

Pediatric intervertebral disc calcification

Halil Dönmez, Ertuğrul Mavili, Türkan İkizceli, R. Kemal Koç

ABSTRACT

Idiopathic calcification of the intervertebral disc is a rare condition in childhood, of unknown etiology. Calcifications are occasionally discovered on routine radiological examination, or on investigation of non-specific symptoms such as neck pain, torticollis, fever, and radiculopathy. We report a case of a 7-year-old boy with intervertebral disc calcification. Clinical and radiological signs are discussed.

Key words: • intervertebral disc • calcification • childhood

Intervertebral disc calcification, although quite frequent in the elderly, is a rare condition in children. The etiology is unknown (1–6). Most cases are asymptomatic and are diagnosed incidentally in routine screening or during evaluation of non-specific clinical complaints such as neck pain, torticollis, fever, and radiculopathy (2, 3, 6).

In this manuscript, we present a rare case of idiopathic intervertebral disc calcification in a 7-year-old boy. Clinical and radiological findings are discussed.

Case report

A 7-year-old boy presented with a chief complaint of recent onset of neck pain. Physical examination revealed limitation in neck movements, but no rigidity. Neurological examination was completely normal. Laboratory findings were within normal limits, and no significant elevation was noted in the erythrocyte sedimentation rate, C-reactive protein, or leukocyte count.

Computed tomography (CT) scanogram revealed increased density consistent with calcification at the level of C6–7 intervertebral disc. Other intervertebral disc levels appeared normal (Fig. 1).

A hyperdense, ellipsoid and ossified (1200 HU) lesion at the level of C6–7 intervertebral disc was noted on cervical CT examination (Fig. 2)

Cervical magnetic resonance imaging (MRI) revealed decreased signal intensity at the C6–7 intervertebral disc on T1- and T2-weighted images. The loss of signal at the disc space was continuous with the lower end-plate and corpus of the C6 vertebra. Hyperintense signal indicating edema was observed in the C6 vertebral corpus on short tau inversion recovery (STIR) sequences. No contrast enhancement was observed in the lesion after intravenous injection of the contrast material. The spinal canal and neural foramina were of normal width (Fig. 3).

Together with the MRI and CT images, the clinical findings suggested an intervertebral disc calcification and reactive changes in the corpus vertebra secondary to the calcification.

Ten days after the administration of non-steroidal anti-inflammatory medications to the patient, the neck pain diminished. Intervertebral disc calcification was observed to be almost completely resolved in the X-rays obtained at the 6-month follow-up visit.

Discussion

Idiopathic intervertebral disc calcification was first reported by Baron (7) in 1924 in a 12-year-old boy; however, the etiology of this condition still has not been determined. Calcification is thought to be related to developmental changes in the nucleus pulposus, and an unknown trigger (e.g., trauma, infection, impaired blood flow) may initiate an inflammatory response (2, 3, 8). Metabolic diseases, hypervitaminosis D, and

From the Departments of Radiology (H.D., E.M. ✉ ertmavili@yahoo.com, T.I.), and Neurosurgery (R.K.K.), Erciyes University School of Medicine, Kayseri, Turkey.

Received 30 March 2007; revision requested 25 April 2007; revision received 4 May 2007; accepted 9 May 2007.

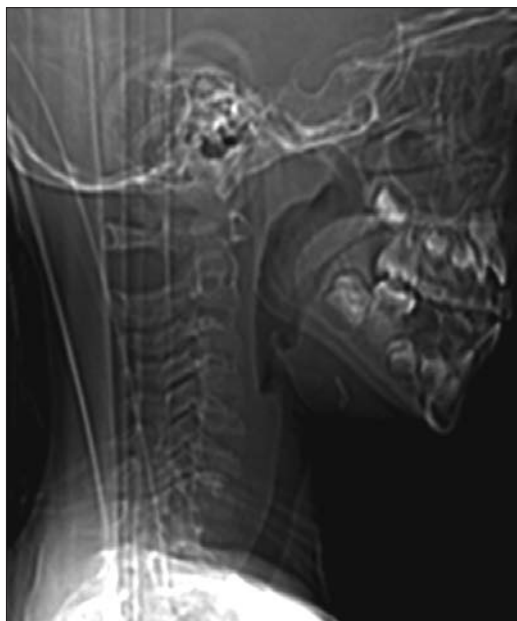


Figure 1. Lateral cervical scanogram shows calcification at the C6–7 intervertebral disc level.

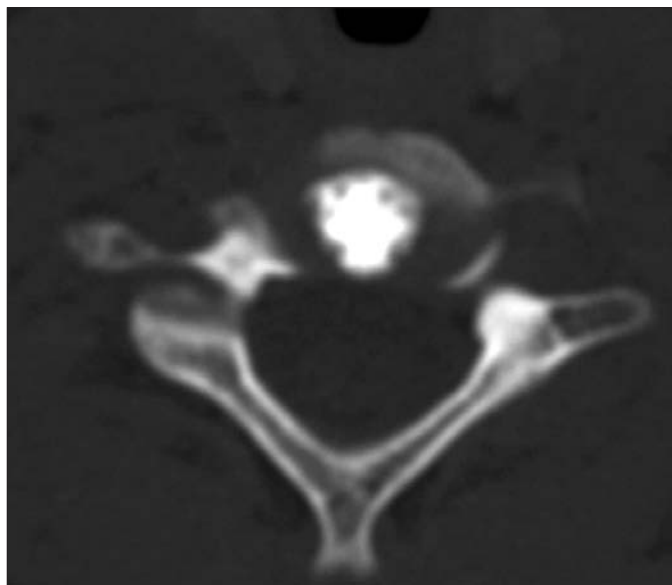


Figure 2. Axial CT image shows dense calcification in the nucleus pulposus, located centrally in the intervertebral disc.

hemolytic anemia also may result in the deposition of calcium in the annulus fibrosus (1, 3). In a study by Smith et al. (9), the condition was reported to be inflammatory. Swick (10) reported that moderate trauma without malignancy or neovascularization may cause the inflammation; however, most patients have no history of trauma (3).

In children, intervertebral disc calcification is seen mostly in boys between the ages of 6 and 10 years (3, 8). Cervical vertebrae are most commonly involved, and the involvement is usually at a single level (2–6). In the study by Gerlach et al. (3), 30–40% of the patients were reported to have intervertebral calcification at several levels. The clinical and radiological findings in our patient, a 7-year-old boy with involvement of only the C6–7 level, are consistent with findings reported in the literature.

In 80–90% of the patients, the most prominent symptom is neck pain. However, neurological findings, including torticollis and radiculopathy, may also accompany intervertebral disc calcification. Leukocytosis and elevated erythrocyte sedimentation rates may be present. In the acute period, disc protrusion may occur and lead to neurological signs due to spinal compression or radicular compression (3, 8). Coventry (11) has reported a disc protrusion in a child with cervical intervertebral disc calcification and dys-

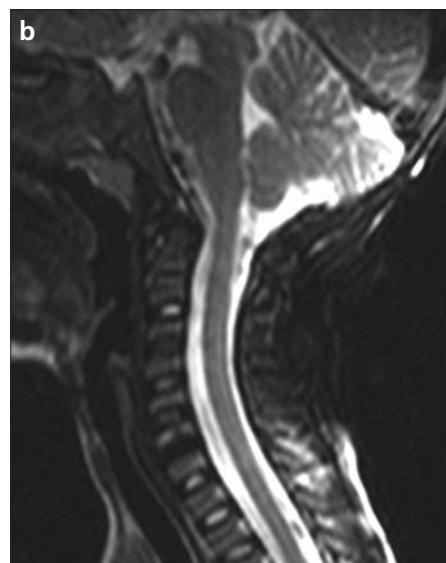
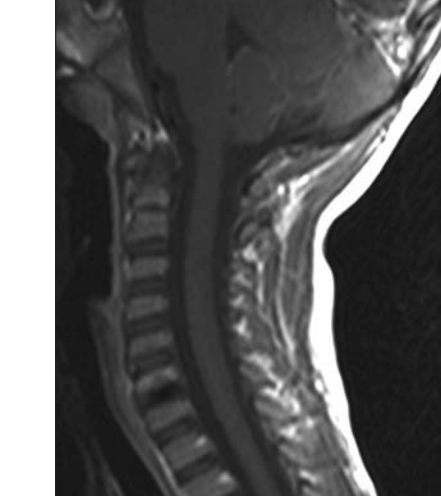


Figure 3. a, b. Sagittal postcontrast T1- (a), and T2-weighted (b) cervical MR images. The C6–7 intervertebral disc shows reduced signal density; the loss of signal in the disc space is continuous with the lower end plate and corpus of the C6 vertebra. The lesion has no marked contrast enhancement on postcontrast T1-weighted sagittal image (a).

phagia secondary to protrusion of the disc. Our patient presented with neck pain only; there were no signs of inflammation such as fever, leukocytosis, or elevated erythrocyte sedimentation rate, and there were no abnormal neurological findings. Pain has been reported to resolve spontaneously in weeks to months (3–5, 8). Calcification of the disc is resorbed as the pain resolves.

Radiologically, calcification of the oval-shaped nucleus pulposus may be demonstrated in X-rays of the inter-

vertebral discs. Any contour irregularities, sclerosis, or torticollis may also be demonstrated (6, 8). Although it takes several months for calcification to be visualized, resolution occurs no later than 6 months after presentation in 95% of patients. Resolution may begin at different levels if there are lesions at multiple levels, and calcification may persist in some patients (3, 6, 8). These patients often present in the long term with chronic back pain, scoliosis, loss of vertebral height, and anterior osteophyte formation (3, 4, 12). In our patient, cal-

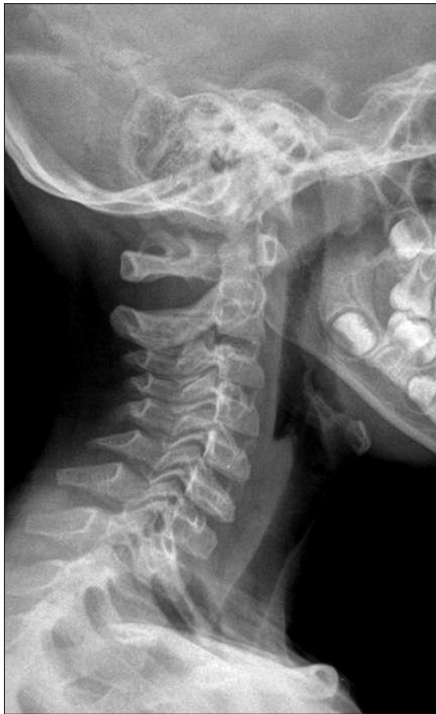

Figure 4. Lateral cervical control radiography at 6 months. No calcification is seen at the C6–7 intervertebral disc level.

cification was not visible in the X-rays obtained at 6 months (Fig. 4), a finding consistent with the literature.

The demonstration of intervertebral disc calcification on CT is more informative when correlated with MRI find-

ings, because MRI is a better modality for the demonstration of reduced intervertebral disc signal intensity, herniated disc, or signs of inflammation (3, 6, 8). In a study by Falcone et al. (6), enthesopathy and edema in the vertebral spongy bone and herniated disc were demonstrated on MRI in the posterior longitudinal ligament. In our patient, MRI revealed only calcification in the intervertebral disc space, and edema in the neighboring C6 corpus vertebra.

Analgesic and anti-inflammatory medications are used in the treatment of idiopathic intervertebral disc calcification; surgical intervention may be indicated in the presence of neurological signs (2–4, 6, 8).

Idiopathic intervertebral disc calcification in children is a benign condition of unknown etiology. It is a rare condition, and is diagnosed incidentally in routine screening or during the evaluation of non-specific clinical complaints.

References

1. Kati M, Tsironi M, Meletis I, Farmakis D, Giakoumis A, Aessopos A. Intervertebral disc calcification in a sickle cell thalassemia patient. *Ann Hematol* 2006; 85:875–877.
2. Harvet G, De Pontual L, Neven B et al. Paediatric intervertebral calcifications: two cases report and review of the literature. *Arch Pediatr* 2004; 11:1457–1461.
3. Gerlach R, Zimmermann M, Kellermann S, Lietz R, Raabel A, Seifert V. Intervertebral disc calcification in childhood: a case report and review of the literature. *Acta Neurochir* 2001; 143:89–93.
4. Morris IM, Sheppard L. The persistence of clinical and radiological features after intervertebral disc calcification of childhood. *Br J Rheumatol* 1986; 25:219–221.
5. Dias MS, Pang D. Juvenile intervertebral disc calcification: recognition, management, and pathogenesis. *Neurosurgery* 1991; 28:130–135.
6. Falcone L, Rossiello P, D'Addetta I, Martino F. Idiopathic intervertebral disc calcification in children: the role of diagnostic imaging. *Reumatismo* 2006; 58:62–65.
7. Baron A. Uber eine neue Erkrankung die Wirbelsaule. *Jahrb Kinderheilkd* 1924; 104:357–360.
8. Bagatur AE, Zorer G, Centel T. Natural history of paediatric intervertebral disc calcification. *Arch Orthop Trauma Surg* 2001; 121:601–603.
9. Smith RA, Vohman MD, Dimon HJ, Averett JE, Misap HH. Calcified intervertebral discs in children. *J Neurosurg* 1977; 46:233–238.
10. Swick HM. Calcification of intervertebral discs in childhood. *J Pediatr* 1975; 86:364–369.
11. Coventry M. Calcification in a cervical disc with anterior protrusion and dysphagia. *J Bone Joint Surg* 1970; 52:1463–1466.
12. Roberts S, Menage J, Eisenstein SM. The cartilage end-plate and intervertebral disc in scoliosis: calcification and other sequelae. *J Orthop Res* 1993; 11:747–757.